

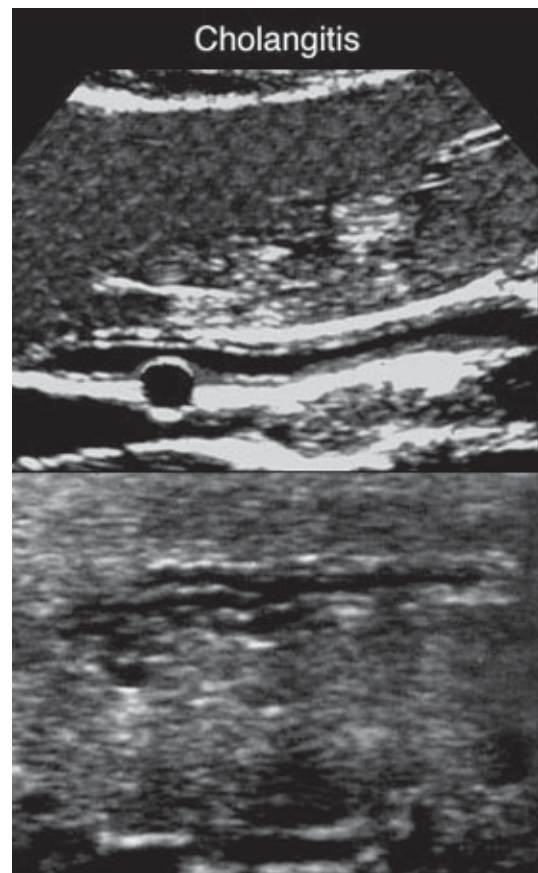
Cholangitis

Infection and Inflammation of the biliary ducts resulting in wall thickening that compromises the lumen of the bile duct.

- Associated with:
 - Cholelithiasis
 - Biliary tract interventions
 - Ulcerative colitis

- Symptoms:
 - Fever
 - Jaundice
 - RUQ pain

- Results in increased:
 - Serum conjugated bilirubin
 - Serum alkaline phosphatase
 - Transaminases
 - Serum amylase and lipase
 - Leukocytosis



Biliary Atresia

Jaundice persisting beyond 4 weeks is most commonly due to biliary atresia or neonatal hepatitis.

- Absence of the extrahepatic biliary tree.

- Associated with polysplenia syndrome with abdominal heterotaxia.

- Sonographically seen as two-vessel portal triad (portal vein and proper hepatic artery).

- Biliary atresia is suspected in infants with jaundice and persistent acholic stools.

- Surgical drainage with the Kasai portoenterostomy is most successful in the treatment of biliary atresia if performed before 90 days of life.