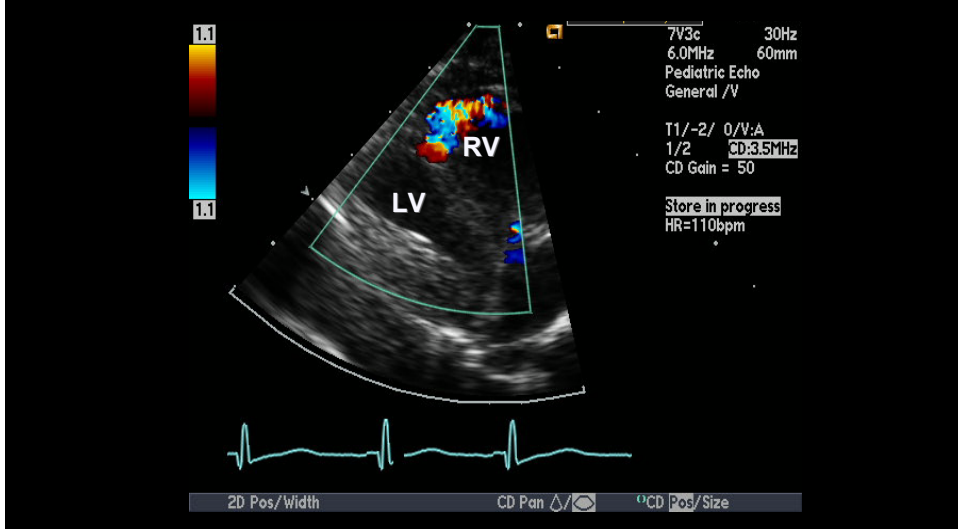


Muscular (Trabecular) V.S.D. (Parasternal Long Axis View)



Membranous V.S.D. (Parasternal Long Axis View)

