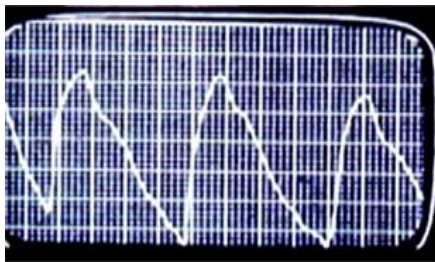


- c. Normal: resting waveforms maintained
- Abnormal: attenuation or flattening of the waveforms in one or more of the positions.

5. Arm positions (patient sits erect off side of the exam table).

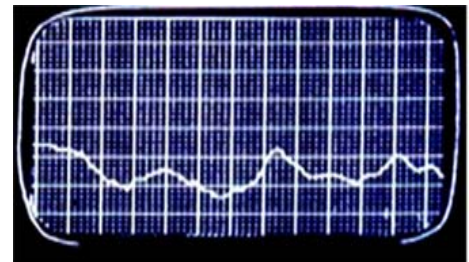
- a. Resting position - hand in lap
- b. Arm at 90° angle
- c. Arm at 180° angle
- d. Exaggerated military stance
- e. Adson Maneuver positioning:
 - Same position as d., head turned sharply to right.
 - Same position as d., head turned sharply to left.
- f. Causative position as described by patient.

6. Example plethysmographic tracings:



NORMAL

Arm position is at 90° with face away.



ABNORMAL

7. Treatment conservative (shoulder exercises) however, surgical treatment done by rib resection with/without scalene splitting.

G. TRAUMA

1. Arterial injuries can result from blunt trauma (e.g., long bone fractures which injure vessels) or penetrating trauma (e.g., stab wounds).
2. Clinical presentation may include open wound, hemorrhage and/or hematoma. There may/may not be distal pulses.
3. Intimal tear can also occur with media and adventitia remaining intact. Pulses may remain palpable initially, but events such as thrombus formation, intimal flap or dissection can occur.