

1. CAPABILITIES

- a. Localize lesion in extra-cranial carotid arteries
- b. Differentiate occlusion from stenosis
- c. Document progression of disease
- d. Identify surface characteristics
- e. Evaluate pulsatile mass

2. LIMITATIONS

Poor visualization secondary to:

- Presence of dressings, skin staples, or sutures
- Size or contour of neck
- Depth or course of vessel
- Acoustic shadowing from calcification

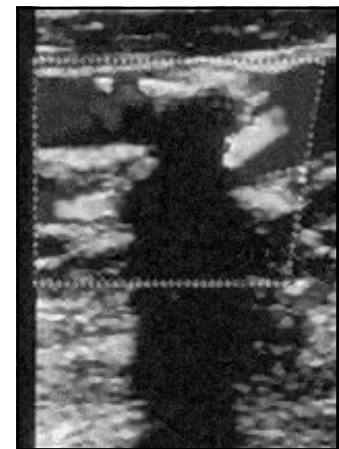


Fig. 14. Calcific shadowing

Over-estimation of the disease process from:

Accelerated flow mistakenly attributed to stenosis instead of:

- Cardiac output
- Tortuous vessel
- Compensatory flow
- Inappropriate Doppler angle

Under-estimation of the disease process:

Accelerated flow not present and/or not detected:

- Jet of accelerated flow missed
- Long, smooth plaque formation
- Stenosis at area of dilatation, i.e. carotid bulb
- Inappropriate Doppler angle